

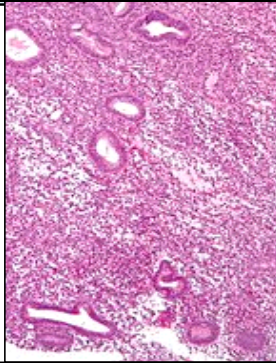
<b>Patient Name</b>	Mrs. GITA DEVI	<b>Client Name</b>	Star Hospital	<b>Specimen Received</b>	10/02/2018
<b>Age/Sex</b>	54/F			<b>Specimen Type</b>	Tissue
<b>Patient ID</b>	011802100234	<b>Client Code</b>	MolQ1255CM	<b>Collection Date</b>	10/02/2018
<b>Specimen ID</b>	MOLQ/B-121/18	<b>Ref. Doctor</b>		<b>Report Date</b>	12/02/2018

## SURGICAL PATHOLOGY REPORT

### Endometrial biopsy

#### DIAGNOSIS

**KINDLY CORRELATE CLINICALLY.**



#### **SPECIMEN:**

Endometrial biopsy.

#### **GROSS:**

1) Received multiple greyish white tissue pieces.

#### **Microscopy**

- 1) Section examined shows only few bite of broken endometrial gland with blood clot with occasional stromal cell.
- 2) No malignant and no granuloma seen in slide received.

**Note :** All biopsy specimen will be stored for 15 (fifteen) days, block and slides for 5 (five) years only from the time of receipt at the laboratory. No request, for any of the above, will be entertained after the due date.

#### **Reference**

- i) Rosai and Ackerman's Surgical Pathology.
- ii) Modern Surgical Pathology.

**Gulshan Yadav, MD**  
Consultant Pathologist