

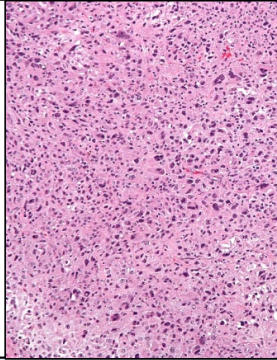
<b>Patient Name</b>	Mrs. PRIYANKA	<b>Client Name</b>	S. S. Polyclinic	<b>Specimen Received</b>	02/02/2018
<b>Age/Sex</b>	26/F			<b>Specimen Type</b>	Tissue
<b>Patient ID</b>	011802020101	<b>Client Code</b>	MolQ1335CM	<b>Collection Date</b>	02/02/2018
<b>Specimen ID</b>	MOLQ/B-91/18	<b>Ref. Doctor</b>		<b>Report Date</b>	07/02/2018

## SURGICAL PATHOLOGY REPORT

### Proliferative phase , Endometrium biopsy.

#### DIAGNOSIS

**PROLIFERATIVE PHASE.**



#### SPECIMEN:

Endometrium biopsy.

#### GROSS:

1) Received multiple greyish white tissue piece.

#### Microscopy

- 1) Section examined shows small endometrial gland having cuboidal lining epithelium with small round nucleus.
- 2) Stroma show mononuclear inflammatory cell.
- 3) No granuloma and no malignant cell seen.

**Note :** All biopsy specimen will be stored for 15 (fifteen)days, block and slides for 5(five) years only from the time of receipt at the laboratory. No request ,for any of the above ,will be entertained after the due date.

#### Reference

- i) Rosai and Ackerman's Surgical Pathology.
- ii) Modern Surgical Pathology.

A handwritten signature in black ink, appearing to read 'Gulshan'.

**Dr. Gulshan Yadav, MD**  
**Consultant Pathologist**