

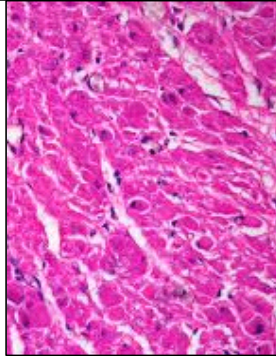
<b>Patient Name</b>	Mrs. MAMPI MANDAL	<b>Client Name</b>	Civil Hospital-P	<b>Specimen Received</b>	30/01/2018
<b>Age/Sex</b>	21/F			<b>Specimen Type</b>	Tissue
<b>Patient ID</b>	011801300207	<b>Client Code</b>	MolQ1681P	<b>Collection Date</b>	30/01/2018
<b>Specimen ID</b>	MOLQ/B-86/18	<b>Ref. Doctor</b>		<b>Report Date</b>	07/02/2018

## SURGICAL PATHOLOGY REPORT

### Bilateral Tubal ectopic pregnancy , Ectopic.

#### DIAGNOSIS

**BILATERAL TUBAL ECTOPIC PREGNANCY.**



#### SPECIMEN:

Ectopic.

#### GROSS:

- 1) Received 6x1.2cm greyish white tissue piece with blood clot.
- 2) Other tube 7x2.8cm greyish white tissue piece with blood clot.

#### Microscopy

- 1) Section examined shows tubal lining epithelium with blood clot and trophoblastic cells.
- 2) Section from the other tube shows tubal lining epithelium with blood clot and trophoblastic cells.

**Note :** All biopsy specimen will be stored for 15 (fifteen)days, block and slides for 5(five) years only from the time of receipt at the laboratory. No request ,for any of the above ,will be entertained after the due date.

#### Reference

- i) Rosai and Ackerman's Surgical Pathology.
- ii) Modern Surgical Pathology.

**Gulshan Yadav, MD**  
Consultant Pathologist