

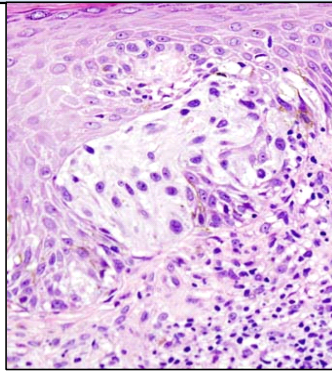
<b>Patient Name</b>	Mrs. PREETI	<b>Client Name</b>	Health Medicos, Rohtak	<b>Specimen Received</b>	31/01/2018
<b>Age/Sex</b>	25/F			<b>Specimen Type</b>	Tissue
<b>Patient ID</b>	011801310150	<b>Client Code</b>	MolQ1394CM	<b>Collection Date</b>	31/01/2018
<b>Specimen ID</b>	MOLQ/B-88/18	<b>Ref. Doctor</b>		<b>Report Date</b>	02/02/2018

## SURGICAL PATHOLOGY REPORT

### Disorder proliferative phase , Endometrial biopsy.

#### DIAGNOSIS

**DISORDER PROLIFERATIVE PHASE.**



#### SPECIMEN

Endometrial biopsy.

#### GROSS

1) Received multiple greyish white tissue piece.

#### Microscopy

- 1) Section examined shows small endometrial gland having round to oval nucleus with few tortuous glands.
- 2) Stroma show mononuclear inflammatory cell.
- 3) AFB :- AFB not seen.

**Note :** All biopsy specimen will be stored for 15 (fifteen) days, block and slides for 5 (five) years only from the time of receipt at the laboratory. No request, for any of the above, will be entertained after the due date.

#### Reference

- i) Rosai and Ackerman's Surgical Pathology.
- ii) Modern Surgical Pathology.

**Gulshan Yadav, MD**  
Consultant Pathologist

Report generated at MolQ Laboratory, Gurgaon