

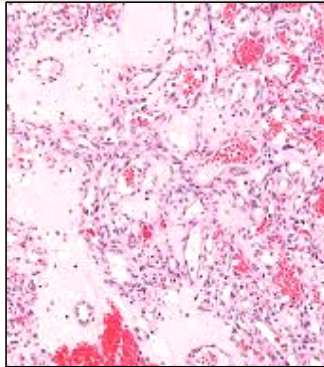
<b>Patient Name</b>	Mrs. SHEELA	<b>Client Name</b>	Agarwal Pathology, Agra	<b>Specimen Received</b>	29/01/2018
<b>Age/Sex</b>	60/F	<b>Client Code</b>	MolQ1420CM	<b>Specimen Type</b>	Tissue
<b>Patient ID</b>	011801290238	<b>Ref. Doctor</b>		<b>Collection Date</b>	29/01/2018
<b>Specimen ID</b>	MOLQ/B-84/18			<b>Report Date</b>	02/02/2018

## SURGICAL PATHOLOGY REPORT

### Hemangioma , Excised mass left nose.

#### DIAGNOSIS

**HEMANGIOMA.**



#### SPECIMEN

Excised mass left nose.

#### GROSS

1) Received multiple greyish white tissue pieces.

#### Microscopy

- 1) Section examined shows fibrocollagenous tissue with large number of blood vessels.
- 2) No malignant cell seen.

**Note :** All biopsy specimen will be stored for 15 (fifteen) days, block and slides for 5 (five) years only from the time of receipt at the laboratory. No request, for any of the above, will be entertained after the due date.

#### Reference

- i) Rosai and Ackerman's Surgical Pathology.
- ii) Modern Surgical Pathology.

**Gulshan Yadav, MD**  
Consultant Pathologist

*Report generated at MolQ Laboratory, Gurgaon*