

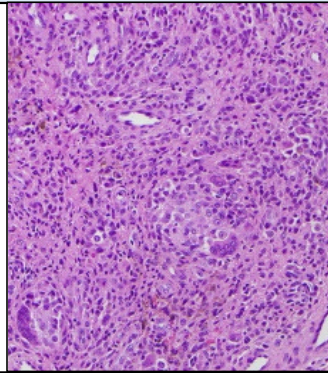
<b>Patient Name</b>	Mrs. SAPNA	<b>Client Name</b>	Cygnus SuperSpeciality	<b>Specimen Received</b>	29/01/2018
<b>Age/Sex</b>	25/F	<b>Hospital</b>	Rewari	<b>Specimen Type</b>	Tissue
<b>Patient ID</b>	011801290175	<b>Client Code</b>	MolQ1687CM	<b>Collection Date</b>	29/01/2018
<b>Specimen ID</b>	MOLQ/B-82/18	<b>Ref. Doctor</b>		<b>Report Date</b>	02/02/2018

## SURGICAL PATHOLOGY REPORT

### Proliferative phase , Endometrium biopsy.

#### DIAGNOSIS

**PROLIFERATIVE PHASE.**



#### SPECIMEN

Endometrium biopsy.

#### GROSS

1) Received multiple greyish white tissue piece.

#### Microscopy

- 1) Section examined shows few broken endometrial gland having cuboidal lining epithelium having small round nucleus.
- 2) Stroma show mononuclear inflammatory cells.
- 3) No malignant and no granuloma seen.

**Note :** All biopsy specimen will be stored for 15 (fifteen)days, block and slides for 5(five) years only from the time of receipt at the laboratory. No request ,for any of the above ,will be entertained after the due date.

#### Reference

- i) Rosai and Ackerman's Surgical Pathology.
- ii) Modern Surgical Pathology.

**Gulshan Yadav, MD**  
Consultant Pathologist

*Report generated at MolQ Laboratory, Gurgaon*