

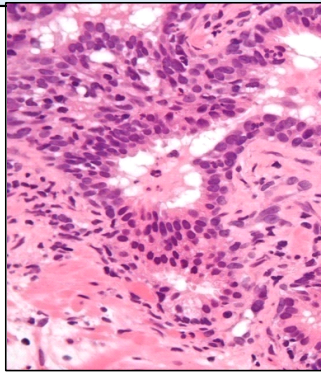
Patient Name	Mrs. SEENAM JOLLY	Client Name	Star Hospital	Specimen Received	29/01/2018
Age/Sex	38/F			Specimen Type	Tissue
Patient ID	011801290168	Client Code	MolQ1255CM	Collection Date	29/01/2018
Specimen ID	MOLQ/B-81/18	Ref. Doctor		Report Date	02/02/2018

SURGICAL PATHOLOGY REPORT

Endometrial polyp and Endometrial biopsy.

DIAGNOSIS

- 1) ENDOMETRIAL POLYP.
- 2) SIMPLE HYPERPLASIA WITHOUT ATYPIA.



SPECIMEN

- 1) Endometrial polyp.
- 2) Endometrial biopsy.

GROSS

- 1) Received 1x1.8cm greyish white tissue piece.
- 2) Received multiple greyish white tissue piece.

Microscopy

- 1.1) Section examined shows mucosal lining epithelium with endometrial glands.
- 1.2) No granuloma and no malignant cell seen.
- 2.1) Section examined show small endometrial gland with few cystically dilated endometrial glands having small round nucleus.
- 2.2) Stroma show mononuclear inflammatory cell.

Note : All biopsy specimen will be stored for 15 (fifteen) days, block and slides for 5 (five) years only from the time of receipt at the laboratory. No request, for any of the above, will be entertained after the due date.

Reference

- i) Rosai and Ackerman's Surgical Pathology.
- ii) Modern Surgical Pathology.

Gulshan Yadav, MD
Consultant Pathologist