

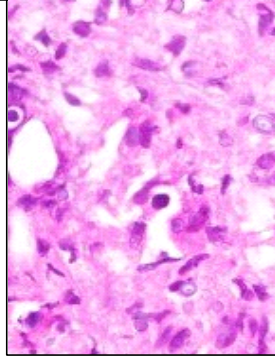
<b>Patient Name</b>	Mrs. SUMAN SHARMA	<b>Client Name</b>	Chirag Diagnostics	<b>Specimen Received</b>	27/01/2018
<b>Age/Sex</b>	36/F	<b>Client Code</b>	MolQ1214CM	<b>Specimen Type</b>	Tissue
<b>Patient ID</b>	011801270042	<b>Ref. Doctor</b>		<b>Collection Date</b>	27/01/2018
<b>Specimen ID</b>	MOLQ/B-78/18			<b>Report Date</b>	31/01/2018

## SURGICAL PATHOLOGY REPORT

**Suggestive of decidual cast , Endometrium tissue.**

### DIAGNOSIS

**SUGGESTIVE OF DECIDUAL CAST.**



#### SPECIMEN:

Endometrium tissue.

#### GROSS:

1) Received tiny tissue piece.

#### Microscopy

- 1) Section examined shows small endometrial gland having columnar lining epithelium having oval nucleus.
- 2) Stroma shows decidual cells and mononuclear inflammatory cells.

**Note :** All biopsy specimen will be stored for 15 (fifteen)days, block and slides for 5(five) years only from the time of receipt at the laboratory. No request ,for any of the above ,will be entertained after the due date.

#### Reference

- i) Rosai and Ackerman's Surgical Pathology.
- ii) Modern Surgical Pathology.

**Gulshan Yadav, MD**  
Consultant Pathologist