

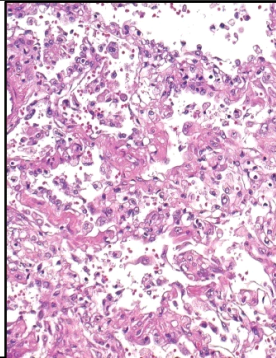
<b>Patient Name</b>	Mrs. RENU W/O SANDEEP	<b>Client Name</b>	Health Medicos, Rohtak	<b>Specimen Received</b>	25/01/2018
<b>Age/Sex</b>	27/F			<b>Specimen Type</b>	Tissue
<b>Patient ID</b>	011801250179	<b>Client Code</b>	MolQ1394CM	<b>Collection Date</b>	25/01/2018
<b>Specimen ID</b>	MOLQ/B-73/18	<b>Ref. Doctor</b>		<b>Report Date</b>	28/01/2018

## SURGICAL PATHOLOGY REPORT

### Disordered proliferative phase , Endometrium biopsy.

#### DIAGNOSIS

**DISORDERED PROLIFERATIVE PHASE.**



#### **SPECIMEN:**

Endometrium biopsy.

#### **GROSS:**

1) Received multiple greyish white tissue piece.

#### **Microscopy**

- 1) Section examined shows small endometrial gland with columnar lining epithelium with round to oval nucleus.
- 2) Stroma show mononuclear inflammatory cell.
- 3) No malignant and no granuloma seen.
- 4) AFB :- AFB not seen.

**Note :** All biopsy specimen will be stored for 15 (fifteen)days, block and slides for 5(five) years only from the time of receipt at the laboratory. No request ,for any of the above ,will be entertained after the due date.

#### **Reference**

- i) Rosai and Ackerman's Surgical Pathology.
- ii) Modern Surgical Pathology.

**Gulshan Yadav, MD**  
**Consultant Pathologist**