

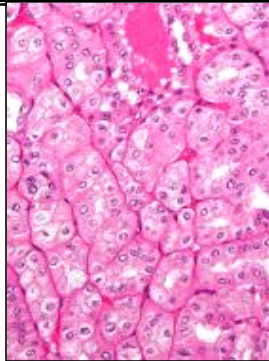
<b>Patient Name</b>	Mrs. USHA	<b>Client Name</b>	Civil Hospital-P	<b>Specimen Received</b>	20/01/2018
<b>Age/Sex</b>	35/F			<b>Specimen Type</b>	Tissue
<b>Patient ID</b>	011801200232	<b>Client Code</b>	MolQ1681P	<b>Collection Date</b>	20/01/2018
<b>Specimen ID</b>	MOLQ/B-62/18	<b>Ref. Doctor</b>		<b>Report Date</b>	27/01/2018

## SURGICAL PATHOLOGY REPORT

### Cholecystitis with cholelithiasis , Gall bladder.

#### DIAGNOSIS

**CHOLECYSTITIS WITH CHOLELITHIASIS.**



#### SPECIMEN:

Gall bladder .

#### GROSS:

- 1) Received 6x1.2cm long gall bladder.
- 2) Cut section show tiny stone.

#### Microscopy

- 1) Section examined shows ulcerative mucosa and rokitansky aschoff sinus with fibrocollagenous tissue.

**Note :** All biopsy specimen will be stored for 15 (fifteen)days, block and slides for 5(five) years only from the time of receipt at the laboratory. No request ,for any of the above ,will be entertained after the due date.

#### Reference

- i) Rosai and Ackerman's Surgical Pathology.
- ii) Modern Surgical Pathology.

**Gulshan Yadav, MD**  
**Consultant Pathologist**