

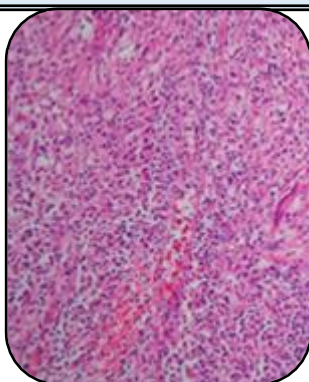
<b>Patient Name</b>	Miss. NIKKI KUMARI	<b>Client Name</b>	Civil Hospital-P	<b>Specimen Received</b>	12/01/2018
<b>Age/Sex</b>	17/F	<b>Client Code</b>	MolQ1681P	<b>Specimen Type</b>	Tissue
<b>Patient ID</b>	011801120047	<b>Ref. Doctor</b>		<b>Collection Date</b>	12/01/2018
<b>Specimen ID</b>	MOLQ/B-37/18			<b>Report Date</b>	17/01/2018

## SURGICAL PATHOLOGY REPORT

Acute appendicitis , Appendix.

### DIAGNOSIS

**ACUTE APPENDICITIS.**



#### SPECIMEN:

Appendix.

#### GROSS:

- 1) Received 6x1.2cm long appendix.
- 2) Cut section show fecolith.

#### Microscopy

- 1) Section examined shows lymphoid follicles with ulcerative mucosa. Deeper tissue show mononuclear inflammatory infiltrate.

**Note :** All biopsy specimen will be stored for 15 (fifteen) days, block and slides for 5 (five) years only from the time of receipt at the laboratory. No request ,for any of the above ,will be entertained after the due date.

#### Reference

- i) Rosai and Ackerman's Surgical Pathology.
- ii) Modern Surgical Pathology.

**Gulshan Yadav, MD**  
Consultant Pathologist