

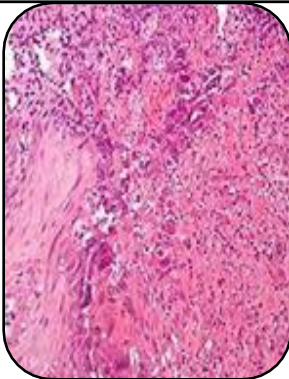
<b>Patient Name</b>	Mrs. KAVITA	<b>Client Name</b>	Civil Hospital-P	<b>Specimen Received</b>	11/01/2018
<b>Age/Sex</b>	24/F	<b>Client Code</b>	MolQ1681P	<b>Specimen Type</b>	Tissue
<b>Patient ID</b>	011801110152	<b>Ref. Doctor</b>		<b>Collection Date</b>	11/01/2018
<b>Specimen ID</b>	MOLQ/B-35/18			<b>Report Date</b>	15/01/2018

## SURGICAL PATHOLOGY REPORT

**Disordered proliferative phase , Endometrium biopsy.**

### DIAGNOSIS

**DISORDERED PROLIFERATIVE PHASE.**



#### **SPECIMEN:**

Endometrium biopsy.

#### **GROSS:**

- 1) Received multiple greyish white tissue pieces.

#### **Microscopy**

- 1) Section examined shows small endometrial gland with tortuous glands having cuboidal lining epithelium having round to oval nucleus.
- 2) Stroma show mononuclear inflammatory cell.
- 3) AFB:-AFB not seen.

**Note :** All biopsy specimen will be stored for 15 (fifteen) days, block and slides for 5 (five) years only from the time of receipt at the laboratory. No request ,for any of the above ,will be entertained after the due date.

#### **Reference**

- i) Rosai and Ackerman's Surgical Pathology.
- ii) Modern Surgical Pathology.

**Gulshan Yadav, MD  
Consultant Pathologist**