

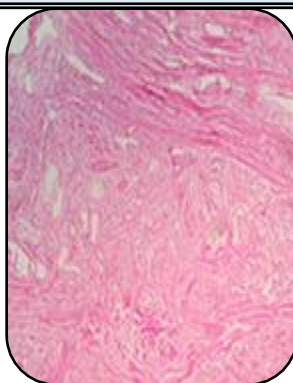
<b>Patient Name</b>	Mr. CHHUTTAN SINGH	<b>Client Name</b>	Uttam Diagnostics, Agra	<b>Specimen Received</b>	20/12/2017
<b>Age/Sex</b>	70/F	<b>Client Code</b>	MolQ1359CM	<b>Specimen Type</b>	Tissue
<b>Patient ID</b>	011712200227	<b>Ref. Doctor</b>		<b>Collection Date</b>	20/12/2017
<b>Specimen ID</b>	MOLQ/B-1023/17			<b>Report Date</b>	24/12/2017

## SURGICAL PATHOLOGY REPORT

### BENIGN PROSTATE HYPERPLASIA , T.U.R.P.

#### DIAGNOSIS

**BENIGN PROSTATE HYPERPLASIA.**



#### SPECIMEN:

T.U.R.P.

#### GROSS:

- 1) Received multiple greyish white tissue piece.
- 2) Measuring 5x4cm in an aggregate.

#### Microscopy

- 1) Section examined shows bilayered prostatic glands with columnar lining epithelium and small round to oval nucleus surrounded by large number of fibrocollagenous tissue are mononuclear inflammatory cell.

**Note :** All biopsy specimen will be stored for 15 (fifteen)days, block and slides for 5(five) years only from the time of receipt at the laboratory. No request ,for any of the above ,will be entertained after the due date.

#### Reference

- i) Rosai and Ackerman's Surgical Pathology.
- ii) Modern Surgical Pathology.

**Gulshan Yadav, MD**  
Consultant Pathologist