

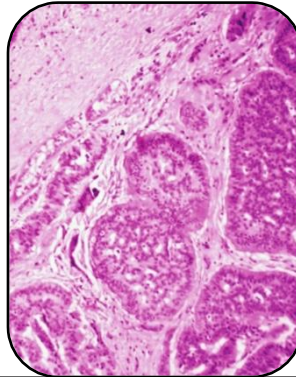
<b>Patient Name</b>	Mrs. KHUSHBOO	<b>Client Name</b>	Civil Hospital-P	<b>Specimen Received</b>	16/12/2017
<b>Age/Sex</b>	28/F	<b>Client Code</b>	MolQ1681P	<b>Specimen Type</b>	Tissue
<b>Patient ID</b>	011712160161	<b>Ref. Doctor</b>		<b>Collection Date</b>	16/12/2017
<b>Specimen ID</b>	MOLQ/B-1001/17			<b>Report Date</b>	23/12/2017

## SURGICAL PATHOLOGY REPORT

**Dermoid cyst , Ovary with tubes.**

### DIAGNOSIS

**DERMOID CYST.**



#### SPECIMEN:

Ovary with tubes.

#### GROSS:

- 1) Received 10x8.7cm long ovary with tube.
- 2) Cut section show necrotic material with hear.

#### Microscopy

- 1) Section examined shows keratin flakes lining epithelium, adipose cell, RBC and tube unremarkable.

**Note :** All biopsy specimen will be stored for 15 (fifteen)days, block and slides for 5(five) years only from the time of receipt at the laboratory. No request ,for any of the above ,will be entertained after the due date.

#### Reference

- i) Rosai and Ackerman's Surgical Pathology.
- ii) Modern Surgical Pathology.

**Gulshan Yadav, MD**  
Consultant Pathologist