

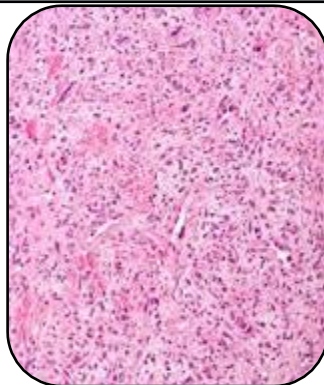
| | | | | | |
|---------------------|-------------------------|--------------------|------------------------|--------------------------|------------|
| Patient Name | Mrs. RACHNA W/O SANDEEP | Client Name | Health Medicos, Rohtak | Specimen Received | 16/12/2017 |
| Age/Sex | 31/F | Client Code | MOLQ1394CM | Specimen Type | Tissue |
| Patient ID | 011712160193 | Ref. Doctor | | Collection Date | 16/12/2017 |
| Specimen ID | MOLQ/B-1002/17 | | | Report Date | 21/12/2017 |

SURGICAL PATHOLOGY REPORT

Proliferative Phase , Endometrial Biopsy.

DIAGNOSIS

PROLIFERATIVE PHASE.



SPECIMEN

Endometrial Biopsy.

GROSS

1) Received multiple greyish white tissue pieces.

Microscopy

- 1) Section examined shows small endometrial gland having cuboidal lining epithelial cell with round to oval nucleus.
- 2) Stroma show mononuclear inflammatory cell.
- 3) AFB :- AFB not seen

Note : All biopsy specimen will be stored for 15 (fifteen)days, block and slides for 5(five) years only from the time of receipt at the laboratory. No request ,for any of the above ,will be entertained after the due date.

Reference

- i) Rosai and Ackerman's Surgical Pathology.
- ii) Modern Surgical Pathology.

A handwritten signature in black ink, appearing to read 'Gulshan', written over a white rectangular background.

Gulshan Yadav, MD
Consultant Pathologist