

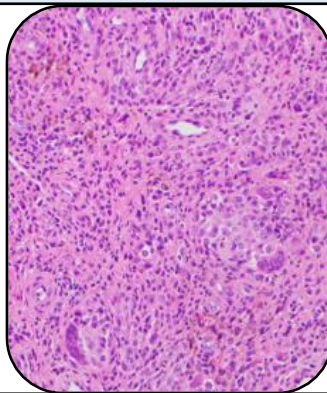
<b>Patient Name</b>	Mrs. NEELAM	<b>Client Name</b>	Cygnus SuperSpeciality	<b>Specimen Received</b>	13/12/2017
<b>Age/Sex</b>	32/F	<b>Hospital, Rewari</b>		<b>Specimen Type</b>	Tissue
<b>Patient ID</b>	011712130182	<b>Client Code</b>	MolQ1687CM	<b>Collection Date</b>	13/12/2017
<b>Specimen ID</b>	MOLQ/B-990/17	<b>Ref. Doctor</b>		<b>Report Date</b>	16/12/2017

## SURGICAL PATHOLOGY REPORT

### Disorder proliferative phase , Endometrial biopsy

#### DIAGNOSIS

#### DISORDER PROLIFERATIVE PHASE



#### SPECIMEN

Endometrial biopsy

#### GROSS

1) Received multiple greyish white tissue piece.

#### Microscopy

- 1) Section examined shows small and tortuous endometrial glands having cuboidal lining epithelial with round to oval nucleus.
- 2) Stromal show mononuclear inflammatory cell.
- 3) No malignant and no granuloma seen.

**Note :** All biopsy specimen will be stored for 15 (fifteen)days, block and slides for 5(five) years only from the time of receipt at the laboratory. No request ,for any of the above ,will be entertained after the due date.

#### Reference

- i) Rosai and Ackerman's Surgical Pathology.
- ii) Modern Surgical Pathology.

**Gulshan Yadav, MD**  
**Consultant Pathologist**