

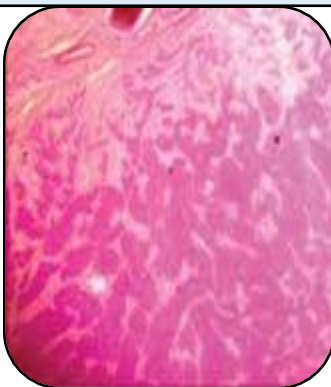
<b>Patient Name</b>	Mrs. MANJU	<b>Client Name</b>	Shikha Health Care	<b>Specimen Received</b>	11/12/2017
<b>Age/Sex</b>	22/F	<b>Client Code</b>	MolQ1519P	<b>Specimen Type</b>	Tissue
<b>Patient ID</b>	011712110166	<b>Ref. Doctor</b>		<b>Collection Date</b>	12/12/2017
<b>Specimen ID</b>	MOLQ/B-983/17			<b>Report Date</b>	16/12/2017

## SURGICAL PATHOLOGY REPORT

### Disorder proliferative phase , Endo. curreting

#### DIAGNOSIS

**DISORDER PROLIFERATIVE PHASE.**



#### SPECIMEN

Endo. curreting

#### GROSS

1) Received autolyzed tissue pieces.

#### Microscopy

- 1) Section examined shows small and tortuous endometrial gland having cuboidal lining epithelium small round nucleus.
- 2) Stromal show mononuclear inflammatory cell.
- 3) No malignant and no granuloma seen.

**Note :** All biopsy specimen will be stored for 15 (fifteen)days, block and slides for 5(five) years only from the time of receipt at the laboratory. No request ,for any of the above ,will be entertained after the due date.

#### Reference

- i) Rosai and Ackerman's Surgical Pathology.
- ii) Modern Surgical Pathology.

**Gulshan Yadav, MD**  
Consultant Pathologist