

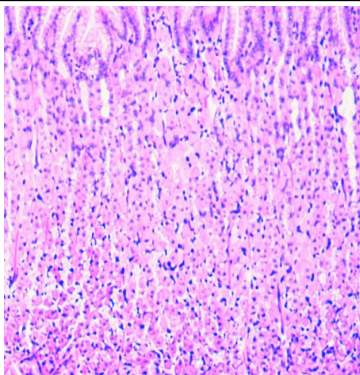
Patient Name	Mrs. NEETU	Client Name	Gobind Hospital	Specimen Received	05/12/2017
Age/Sex	30/M	Client Code	MolQ1232CM	Specimen Type	Tissue
Patient ID	011712050086	Ref. Doctor		Collection Date	05/12/2017
Specimen ID	MOLQ/B-969/17			Report Date	11/12/2017

SURGICAL PATHOLOGY REPORT

Left Fallopian Tube

DIAGNOSIS

LEFT FALLOPIAN TUBE CONFIRM AND UNREMARKABLE.



SPECIMEN

Left Fallopian Tube

GROSS

1) Received 1x0.5cm greyish white tissue piece.

Microscopy

1) Section examined shows tubal lining epithelium with fibrocollagenous tissue.

Note : All biopsy specimen will be stored for 15 (fifteen)days, block and slides for 5(five) years only from the time of receipt at the laboratory. No request ,for any of the above ,will be entertained after the due date.

Reference

- i) Rosai and Ackerman's Surgical Pathology.
- ii) Modern Surgical Pathology.

Gulshan Yadav, MD
Consultant Pathologist