

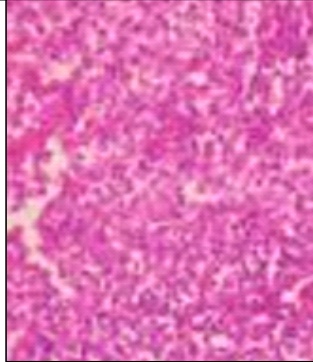
<b>Patient Name</b>	Mr. PRAKASH SHARMA	<b>Client Name</b>	Lifeaid Wellness Centre	<b>Specimen Received</b>	03/12/2017
<b>Age/Sex</b>	34/F			<b>Specimen Type</b>	Tissue
<b>Patient ID</b>	011712030033	<b>Client Code</b>	MOLQ1476CM	<b>Collection Date</b>	03/12/2017
<b>Specimen ID</b>	MOLQ/B-962/17	<b>Ref. Doctor</b>		<b>Report Date</b>	08/12/2017

## SURGICAL PATHOLOGY REPORT

### Cholecystitis with cholelithiasis, Gall bladder.

#### DIAGNOSIS

#### CHOLECYSTITIS WITH CHOLELITHIASIS



#### SPECIMEN

Gall bladder.

#### GROSS

- Received 6x2cm long gall bladder with tiny stone.

#### Microscopy

- Section examined shows ulcerative mucosa and rokitansky aschoff sinus with fibrocollagenous tissue.

**Note :** All biopsy specimen will be stored for 15 (fifteen)days, block and slides for 5(five) years only from the time of receipt at the laboratory. No request ,for any of the above ,will be entertained after the due date.

#### Reference

- Rosai and Ackerman's Surgical Pathology.
- Modern Surgical Pathology.

**Gulshan Yadav, MD**  
Consultant Pathologist

Report generated at MolQ Laboratory, Gurgaon