

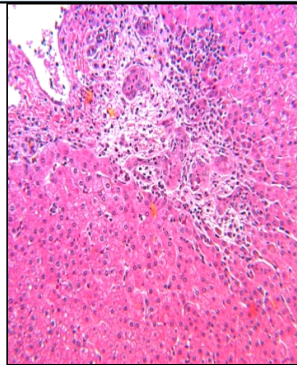
<b>Patient Name</b>	Mr. ANWAR KHAN	<b>Client Name</b>	Swami Amardev Hospital	<b>Specimen Received</b>	01/12/2017
<b>Age/Sex</b>	45/M			<b>Specimen Type</b>	Tissue
<b>Patient ID</b>	011712010141	<b>Client Code</b>	MolQ1510CM	<b>Collection Date</b>	01/12/2017
<b>Specimen ID</b>	MOLQ/B-955/17	<b>Ref. Doctor</b>		<b>Report Date</b>	07/12/2017

## SURGICAL PATHOLOGY REPORT

### Infective cystic lesion ( Epidermal ), Cystic lesion

#### DIAGNOSIS

#### INFECTIVE CYSTIC LESION ( EPIDERMAL )



#### SPECIMEN

Cystic lesion.

#### GROSS

- 1) Received tiny tissue 0.5x0.5cm greyish white tissue piece.

#### Microscopy

- 1) Section examined shows fibrocollagenous tissue, blood vessel and inflammatory cell ( lymphocyte , polymorph ) with karetin flakes.
- 2) No granuloma seen.

**Note :** All biopsy specimen will be stored for 15 (fifteen)days, block and slides for 5(five) years only from the time of receipt at the laboratory. No request ,for any of the above ,will be entertained after the due date.

#### Reference

- i) Rosai and Ackerman's Surgical Pathology.
- ii) Modern Surgical Pathology.

**Gulshan Yadav, MD**  
**Consultant Pathologist**