

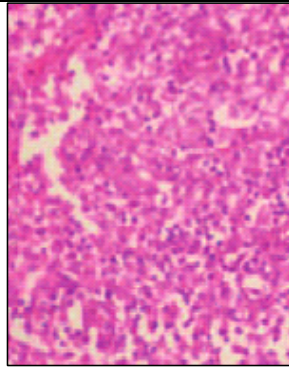
Patient Name	Mr. HETPAL	Client Name	Civil Hospital-P	Specimen Received	28/11/2017
Age/Sex	33/F			Specimen Type	Tissue
Patient ID	011711280104	Client Code	MolQ1681P	Collection Date	28/11/2017
Specimen ID	MOLQ/B-943/17	Ref. Doctor		Report Date	02/12/2017

SURGICAL PATHOLOGY REPORT

Cholecystitis with cholelithiasis, Gall bladder

DIAGNOSIS

CHOLECYSTITIS WITH CHOLELITHIASIS.



SPECIMEN

Gall bladder

Microscopy

- 1) Section examined shows ulcerative mucosa and Rokitansky-Aschoff sinuses with lymphocytes within fibrocollagenous tissue.

Note : All biopsy specimens will be stored for 15 (fifteen) days, blocks and slides for 5 (five) years only from the time of receipt at the laboratory. No request for any of the above will be entertained after the due date.

Reference

- i) Rosai and Ackerman's Surgical Pathology.
- ii) Modern Surgical Pathology.

GROSS

- 1) Received 6x3cm long gall bladder.
- 2) Cut section shows stone.

A handwritten signature in black ink, appearing to read 'Gulshan', written over a light-colored rectangular background.

Gulshan Yadav, MD
Consultant Pathologist