

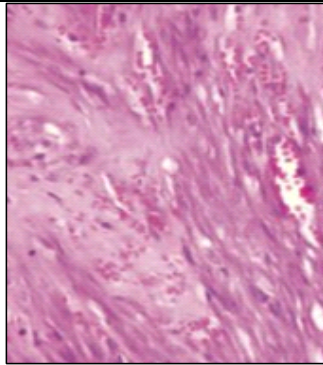
Patient Name	Mr. SUJAN SINGH	Client Name	Civil Hospital-P	Specimen Received	25/11/2017
Age/Sex	42/M			Specimen Type	Tissue
Patient ID	011711250054	Client Code	MolQ1681P	Collection Date	25/11/2017
Specimen ID	MOLQ/B-936/17	Ref. Doctor		Report Date	01/12/2017

SURGICAL PATHOLOGY REPORT

Testis.

DIAGNOSIS

SUPPURATIVE ORCHITIS.



SPECIMEN

Testis.

GROSS

- 1) Received 7x5cm greyish white tissue piece.
- 2) Cut section show necrotic material.

Microscopy

- 1) Section examined shows fibrocollagenous tissue, polymorph, pus cell, lymphocyte in an necrotic background with distorted architecture.
- 2) Section also show atrophic seminiferous tissue.

Note : All biopsy specimen will be stored for 15 (fifteen)days, block and slides for 5(five) years only from the time of receipt at the laboratory. No request ,for any of the above ,will be entertained after the due date.

Reference

- i) Rosai and Ackerman's Surgical Pathology.
- ii) Modern Surgical Pathology.

Gulshan Yadav, MD
Consultant Pathologist

Report generated at MolQ Laboratory, Gurgaon