

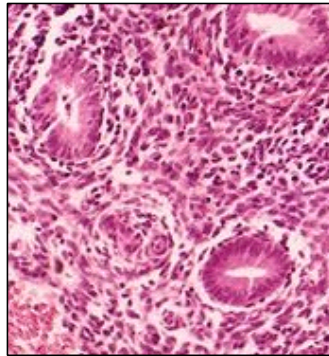
<b>Patient Name</b>	Mrs. BUNU	<b>Client Name</b>	Kailash Nursing Home	<b>Specimen Received</b>	18/11/2017
<b>Age/Sex</b>	29/F			<b>Specimen Type</b>	Tissue
<b>Patient ID</b>	011711180185	<b>Client Code</b>	MOLQ1171P	<b>Collection Date</b>	18/11/2017
<b>Specimen ID</b>	MOLQ/B-907/17	<b>Ref. Doctor</b>		<b>Report Date</b>	25/11/2017

## SURGICAL PATHOLOGY REPORT

### Early secretory phase , Endometrium

#### DIAGNOSIS

#### EARLY SECRETORY PHASE



#### SPECIMEN

Endometrium

#### GROSS

- 1) Received multiple greyish white tissue pieces.

#### Microscopy

- 1) Section examined shows small endometrial gland with tortuous glands having columnar cell with round to oval nucleus and vesicles.
- 2) Stroma show mononuclear inflammatory cell.
- 3) AFB :- AFB not seen.

**Note :** All biopsy specimen will be stored for 15 (fifteen) days, block and slides for 5 (five) years only from the time of receipt at the laboratory. No request, for any of the above, will be entertained after the due date.

#### Reference

- i) Rosai and Ackerman's Surgical Pathology.
- ii) Modern Surgical Pathology.

**Gulshan Yadav, MD**  
Consultant Pathologist