

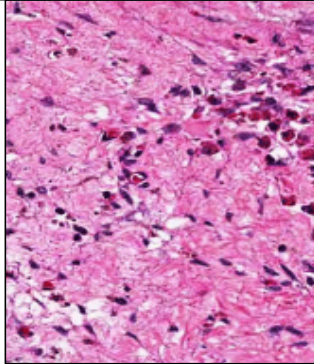
| | | | | | |
|---------------------|-------------------|--------------------|----------------|--------------------------|-------------------|
| Patient Name | Mrs. GEETA | Client Name | Vedic Hospital | Specimen Received | 17/11/2017 |
| Age/Sex | 43/F | | | Specimen Type | Tissue |
| Patient ID | 011711170037 | Client Code | MOLQ 1492CM | Collection Date | 17/11/2017 |
| Specimen ID | MOLQ/B-891/17 | Ref. Doctor | | Report Date | 23/11/2017 |

SURGICAL PATHOLOGY REPORT

Hemorrhagic cyst ovary , Uterus with cervix.

DIAGNOSIS

HEMORRHAGIC CYST OVARY.



SPECIMEN

Uterus with cervix.

GROSS

- 1) Received 9.4x3.1cm long uterus with cervix with unilateral adnexa.
- 2) Ovary size 3x1.8cm.

Microscopy

- 1) Section examined shows Small endometrial gland in proliferative phase.
- 2) Myometrium show muscle bundle.
- 3) Cervix show mononuclear inflammatory cell.
- 4) Ovary show hemorrhagic cyst.
- 5) Tube unremarkable.

Note : All biopsy specimen will be stored for 15 (fifteen) days, block and slides for 5 (five) years only from the time of receipt at the laboratory. No request, for any of the above, will be entertained after the due date.

Reference

- i) Rosai and Ackerman's Surgical Pathology.
- ii) Modern Surgical Pathology.

Gulshan Yadav, MD
Consultant Pathologist