

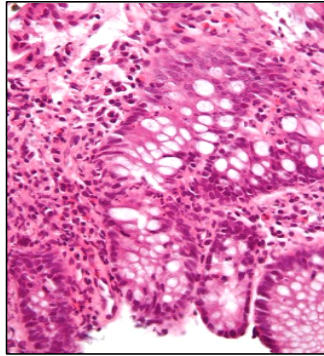
Patient Name	Mr. BALBEER	Client Name	Star Hospital	Specimen Received	11/11/2017
Age/Sex	33/M			Specimen Type	Tissue
Patient ID	011711110230	Client Code	MOLQ1255CM	Collection Date	11/11/2017
Specimen ID	MOLQ/B-867/17	Ref. Doctor	Dr. Gopal	Report Date	22/11/2017

SURGICAL PATHOLOGY REPORT

Chronic infective lesion , Left axilla sinus.

DIAGNOSIS

CHRONIC INFECTIVE LESION



GROSS

- 1) Received 3x3cm greyish white tissue piece.

SPECIMEN

Left axilla sinus.

Microscopy

- 1) Section examined shows Squamous lining epithelium.
 - 2) Deeper tissue show fibrocollagenous tissue, blood vessel with mononuclear inflammatory infiltrate.
 - 3) No malignant cell seen.
- 4) Note :** All biopsy specimen will be stored for 15 (fifteen)days, block and slides for 5(five) years only from the time of receipt at the laboratory. No request ,for any of the above ,will be entertained after the due date.

Reference

- i) Rosai and Ackerman's Surgical Pathology.
- ii) Modern Surgical Pathology.

Gulshan Yadav, MD
Consultant Pathologist