

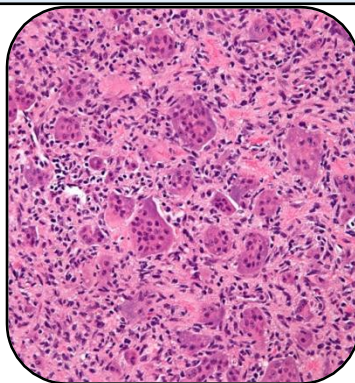
<b>Patient Name</b>	Mr. ANIL SHARMA	<b>Client Name</b>	Lalita Memorial	<b>Specimen Received</b>	08/11/2017
<b>Age/Sex</b>	50/F	<b>Hospital Pvt. Ltd. (Rewari)</b>		<b>Specimen Type</b>	Tissue
<b>Patient ID</b>	011711080231	<b>Client Code</b>	MolQ1652P	<b>Collection Date</b>	08/11/2017
<b>Specimen ID</b>	MOLQ/B-860/17	<b>Ref. Doctor</b>		<b>Report Date</b>	15/11/2017

## SURGICAL PATHOLOGY REPORT

### Cyst scalp.

#### DIAGNOSIS

**BENIGN MESENCHYMAL KEMION LESION.**



#### SPECIMEN

Cyst scalp.

#### GROSS

1) Received 1x1cm greyish white tissue piece.

#### Microscopy

- 1) Section examined shows squamous lining epithelial cell.
- 2) Deeper tissue show fibrocollagenous tissue , blood vessel , macture adipose cell.

**Note :** All biopsy specimen will be stored for 15 (fifteen)days, block and slides for 5(five) years only from the time of receipt at the laboratory. No request ,for any of the above ,will be entertained after the due date.

#### Reference

- i) Rosai and Ackerman's Surgical Pathology.
- ii) Modern Surgical Pathology.

**Gulshan Yadav, MD**  
**Consultant Pathologist**