

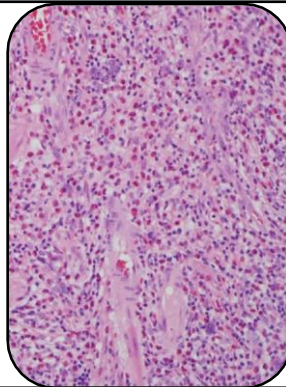
Patient Name	Baby. PREETI	Client Name	Bio-Science X Ray Lab	Specimen Received	25/10/2017
Age/Sex	7/F	Client Code	MOLQ1139CW	Specimen Type	Tissue
Patient ID	011710250136	Ref. Doctor		Collection Date	25/10/2017
Specimen ID	MOLQ/B-824/17			Report Date	30/10/2017

SURGICAL PATHOLOGY REPORT

Inflammatory polyp , Nostril polyp

DIAGNOSIS

INFLAMMATORY POLYP.



SPECIMEN

Nostril polyp

GROSS

1) Received 2x4cm and 2x3cm greyish white tissue piece.

Microscopy

- 1) Section examined shows mucosal lining epithelium having round to oval nucleus with fibrocollagenous tissue and blood vessel with inflammatory cell .
- 2) No granuloma and no malignant cell seen.

Note : All biopsy specimen will be stored for 15 (fifteen)days, block and slides for 5(five) years only from the time of receipt at the laboratory. No request ,for any of the above ,will be entertained after the due date.

Reference

- i) Rosai and Ackerman's Surgical Pathology.
- ii) Modern Surgical Pathology.

Gulshan Yadav, MD
Consultant Pathologist