

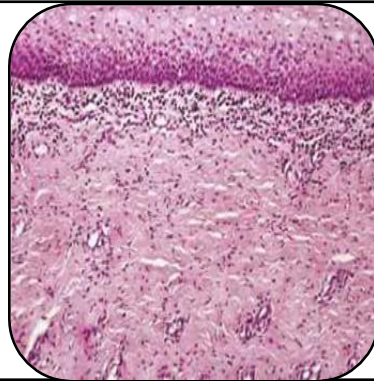
<b>Patient Name</b>	Mrs. SANDHYA	<b>Client Name</b>	Lalita Memorial	<b>Specimen Received</b>	20/10/2017
<b>Age/Sex</b>	28/F		Hospital Pvt. Ltd. (Rewari)	<b>Specimen Type</b>	Tissue
<b>Patient ID</b>	011710140249	<b>Client Code</b>	MolQ1652P	<b>Collection Date</b>	20/10/2017
<b>Specimen ID</b>	MOLQ/B-806/17	<b>Ref. Doctor</b>		<b>Report Date</b>	27/10/2017

## SURGICAL PATHOLOGY REPORT

### Normal placental tissue with mild inflammation , Placenta

#### DIAGNOSIS

**NORMAL PLACENTAL TISSUE WITH MILD INFLAMMATION**



#### SPECIMEN

Placenta.

#### GROSS

1) Received 4x3cm greyish white tissue piece.

#### Microscopy

- 1) Section examined shows trophoblastic cell , villi , decidua cells .
- 2) Section also show area of inflammatory cell.

#### Reference

- i) Rosai and Ackerman's Surgical Pathology.
- ii) Modern Surgical Pathology.

**Gulshan Yadav, MD**  
**Consultant Pathologist**