

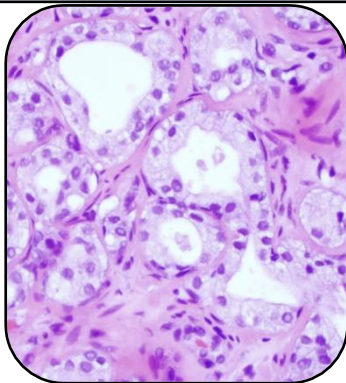
| | | | | | |
|---------------------|---------------|--------------------|--------------------------------------|--------------------------|------------|
| Patient Name | Mr. KAWAR LAL | Client Name | Goyal Ultrasound & Diagnostic Center | Specimen Received | 17/10/2017 |
| Age/Sex | 65/M | Client Code | MolQ1664P | Specimen Type | Tissue |
| Patient ID | 011710170127 | Ref. Doctor | | Collection Date | 17/10/2017 |
| Specimen ID | MOLQ/B-812/17 | | | Report Date | 23/10/2017 |

SURGICAL PATHOLOGY REPORT

Benign prostatic hyperplasia , T.U.R.P

DIAGNOSIS

BENIGN PROSTATIC HYPERPLASIA.



SPECIMEN

T.U.R.P

GROSS

- 1) Received multiple greyish white tissue piece .
- 2) 5x6cm in aggregate .

Microscopy

- 1) Section examined shows bilayered prostatic glands with columnar lining epithelium and with small round to oval nucleus surrounded by large number of fibro collagenous tissue and mononuclear inflammatory cells .

Note : All biopsy specimen will be stored for 15 (fifteen)days, block and slides for 5(five) years only from the time of receipt at the laboratory. No request ,for any of the above ,will be entertained after the due date.

Reference

- i) Rosai and Ackerman's Surgical Pathology.
- ii) Modern Surgical Pathology.

Gulshan Yadav, MD
Consultant Pathologist