

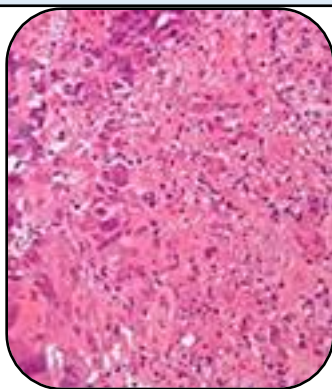
Patient Name Mr. SONU	Client Name Care Diagnostics centre	Specimen Received 16/10/2017
Age/Sex 18/M		Specimen Type Tissue
Patient ID 011710160259	Client Code MolQ1522P	Collection Date 16/10/2017
Specimen ID MOLQ/B-809/17	Ref. Doctor	Report Date 23/10/2017

SURGICAL PATHOLOGY REPORT

Acute appendicitis , Appendix

DIAGNOSIS

ACUTE APPENDICITIS



SPECIMEN

Appendix

GROSS

- 1) Received 7.2x2cm greyish white tissue piece autolyzed
- 2) Cut section show fecolith

Microscopy

- 1) Section examined shows lymphoid follicals with ulcerative mucosa .
- 2) Deeper tissue shows inflammatory infiltrate .

Note : All biopsy specimen will be stored for 15 (fifteen)days, block and slides for 5(five) years only from the time of receipt at the laboratory. No request ,for any of the above ,will be entertained after the due date.

Reference

- i) Rosai and Ackerman's Surgical Pathology.
- ii) Modern Surgical Pathology.

Gulshan Yadav, MD
Consultant Pathologist