

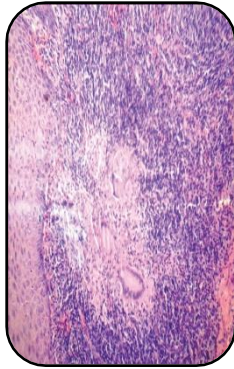
<b>Patient Name</b>	Master. AARAV	<b>Client Name</b>	S.R. Diagnostics	<b>Specimen Received</b>	03/10/17
<b>Age/Sex</b>	05/M	<b>Client Code</b>	MolQ1528CM	<b>Specimen Type</b>	Tissue
<b>Patient ID</b>	011710030316	<b>Ref. Doctor</b>		<b>Collection Date</b>	03/10/17
<b>Specimen ID</b>	MOLQ/B-767/17			<b>Report Date</b>	05/10/17

## SURGICAL PATHOLOGY REPORT

### Granulomatous reaction , Swelling Right Arm

#### DIAGNOSIS

**GRANULOMATOUS REACTION.**



#### SPECIMEN:

Swelling Right Arm

#### GROSS :

- 1) Received 1x2cm greyish white tissue pieces.

#### Microscopy

- 1) Section examined shows mononuclear inflammatory cells, fibrocollagenous tissue, calcification with multinucleated giant cells and necrosis with histiocytes.

**Note :** All biopsy specimen will be stored for 15 (fifteen)days, block and slides for 5(five) years only from the time of receipt at the laboratory. No request ,for any of the above ,will be entertained after the due date.

#### Reference

- i) Rosai and Ackerman's Surgical Pathology.
- ii) Modern Surgical Pathology.

**Gulshan Yadav, MD**  
Consultant Pathologist