

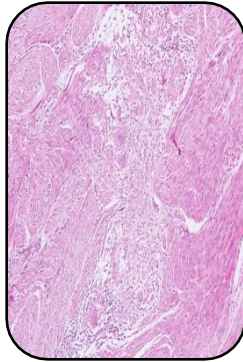
<b>Patient Name</b>	Mrs. DEEPA	<b>Client Name</b>	Apex Citi Hospital	<b>Specimen Received</b>	29/09/17
<b>Age/Sex</b>	32/F	<b>Client Code</b>	MolQ1580P	<b>Specimen Type</b>	Tissue
<b>Patient ID</b>	011709290096	<b>Ref. Doctor</b>	DR VANDANA	<b>Collection Date</b>	29/09/17
<b>Specimen ID</b>	MOLQ/B-757/17			<b>Report Date</b>	03/10/17

## SURGICAL PATHOLOGY REPORT

### Disordered proliferative phase , Endometrial Biopsy

#### DIAGNOSIS

**DISORDERED PROLIFERATIVE PHASE.**



#### GROSS

- 1) Received multiple greyish white tissue pieces.

#### SPECIMEN

Endometrial Biopsy

#### Microscopy

- 1) Section examined shows small endometrial glands having columnar lining epithelium with vacuoles in some glands having oval nucleus.
- 2) Stroma shows mononuclear inflammatory cells.
- 3) No granuloma and no malignant cells seen.

**Note :** All biopsy specimen will be stored for 15 (fifteen)days, block and slides for 5(five) years only from the time of receipt at the laboratory. No request ,for any of the above ,will be entertained after the due date.

#### Reference

- i) Rosai and Ackerman's Surgical Pathology.
- ii) Modern Surgical Pathology.

A handwritten signature in black ink, appearing to read 'Gulshan', written over a white rectangular background.

**Gulshan Yadav, MD**  
**Consultant Pathologist**

*Report generated at MolQ Laboratory, Gurgaon*