

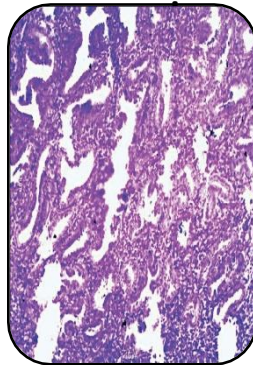
Patient Name	MRS. CHANDNI DEVI	Client Name	Civil Hospital-P	Specimen Received	27/09/17
Age/Sex	30/F	Client Code	MolQ1681P	Specimen Type	Tissue
Patient ID	011709270148	Ref. Doctor		Collection Date	27/09/17
Specimen ID	MOLQ/B-752/17			Report Date	28/09/17

SURGICAL PATHOLOGY REPORT

Simple hyperplasia without Atypia , Endometrial

DIAGNOSIS

SIMPLE HYPERPLASIA WITHOUT ATYPIA.



SPECIMEN

Endometrial

GROSS

- 1) Received multiple greyish white tissue piece.

Microscopy

- 1) Section examined shows small endometrial gland in proliferative phase with cystically dilated gland .
- 2) Stroma shows mononuclear inflammatory cell .

Note : All biopsy specimen will be stored for 15 (fifteen)days, block and slides for 5(five) years only from the time of receipt at the laboratory. No request ,for any of the above ,will be entertained after the due date.

Reference

- i) Rosai and Ackerman's Surgical Pathology.
- ii) Modern Surgical Pathology.

Gulshan Yadav, MD
Consultant Pathologist