

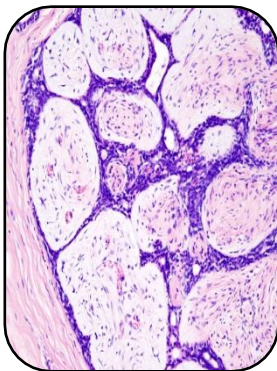
<b>Patient Name</b>	Mrs. ASHA	<b>Client Name</b>	Lifeaid Wellness Centre	<b>Specimen Received</b>	18/09/17
<b>Age/Sex</b>	38/F	<b>Client Code</b>	MOLQ1476CM	<b>Specimen Type</b>	Tissue
<b>Patient ID</b>	011709180009	<b>Ref. Doctor</b>		<b>Collection Date</b>	18/09/17
<b>Specimen ID</b>	MOLQ/B-718/17			<b>Report Date</b>	22/09/17

## SURGICAL PATHOLOGY REPORT

### Benign breast lesion (Fibroadenoma) , Fibro adenoma breast

#### DIAGNOSIS

**BENIGN BREAST LESION (FIBROADENOMA).**



#### SPECIMEN

Fibro adenoma breast

#### GROSS

1) Received 4x1.8cm fibro fatty tissue.

#### Microscopy

1) Section examined shows stromal cells ( fibrocollagenous , blood vessels and mature adipose cells ) with few ductal cells and mononuclear inflammatory cells.

**Note :** All biopsy specimen will be stored for 15 (fifteen)days, block and slides for 5(five) years only from the time of receipt at the laboratory. No request ,for any of the above ,will be entertained after the due date.

#### Reference

- i) Rosai and Ackerman's Surgical Pathology.
- ii) Modern Surgical Pathology.

A handwritten signature in black ink, appearing to read 'Gulshan', written over a white rectangular background.

**Gulshan Yadav, MD**  
**Consultant Pathologist**