

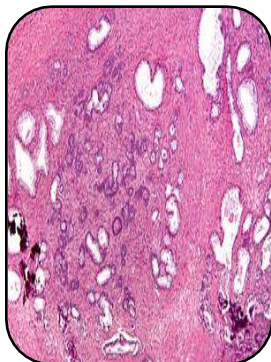
Patient Name	MR. RAMESHWAR	Client Name	Navjeevan Hospital (Rohtak)	Specimen Received	14/09/17
Age/Sex	85/M	Client Code	MOLQ 1297CM	Specimen Type	Tissue
Patient ID	011709140239	Ref. Doctor		Collection Date	14/09/17
Specimen ID	MOLQ/B-711/17			Report Date	16/09/17

SURGICAL PATHOLOGY REPORT

Benign prostatic hyperplasia , T.u.r.p

DIAGNOSIS

BENIGN PROSTATIC HYPERPLASIA



SPECIMEN

T.u.r.p

GROSS

- 1) Received multiple greyish white tissue piece measuring 5x3cm in aggregate.

Microscopy

- 1) Section examined shows bilayered prostatic glands with columnar lining epithelium and projection in the lumen with small round to oval nucleus surrounded by large number of fibrocollagenous tissue and mononuclear inflammatory cells

Note : All biopsy specimen will be stored for 15 (fifteen)days, block and slides for 5(five) years only from the time of receipt at the laboratory. No request ,for any of the above ,will be entertained after the due date.

Reference

- i) Rosai and Ackerman's Surgical Pathology.
- ii) Modern Surgical Pathology.

Gulshan Yadav, MD
Consultant Pathologist