

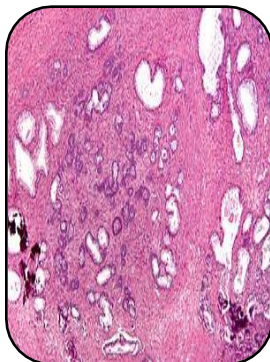
Patient Name	MR.PEHALWAN	Client Name	S.R. Diagnostics	Specimen Received	14/09/17
Age/Sex	62/M	Client Code	MolQ1528CM	Specimen Type	Tissue
Patient ID	011709140162			Collection Date	14/09/17
Specimen ID	MOLQ/B-710/17	Ref. Doctor	DR.NAVIN HOSPITAL	Report Date	16/09/17

SURGICAL PATHOLOGY REPORT

Benign prostatic hyperplasia , T.u.r.p

DIAGNOSIS

BENIGN PROSTATIC HYPERPLASIA



SPECIMEN

T.u.r.p

GROSS

- 1) Received multiple greyish white tissue piece 4x3cm in aggregate .

Microscopy

- 1) Section examined shows bilayered prostatic glands with columnar lining epithelium and projection in the lumen with small round to oval nucleus surrounded by large number of fibrocollagenous tissue and mononuclear inflammatory cells

Note : All biopsy specimen will be stored for 15 (fifteen)days, block and slides for 5(five) years only from the time of receipt at the laboratory. No request ,for any of the above ,will be entertained after the due date.

Reference

- i) Rosai and Ackerman's Surgical Pathology.
- ii) Modern Surgical Pathology.

Gulshan Yadav, MD
Consultant Pathologist