

**Patient Name** Mrs. SAVITA  
**Age/Sex** 30/F  
**Patient ID** 011709140077  
**Specimen ID** MOLQ/B-704/17

**Client Name** Civil Hospital-P  
**Client Code** MolQ1681P  
**Ref. Doctor**

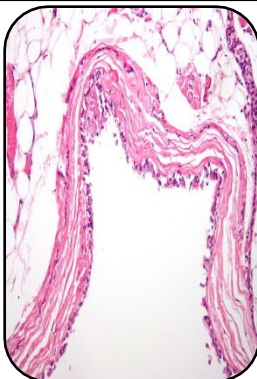
**Specimen Received** 14/09/17  
**Specimen Type** Tissue  
**Collection Date** 14/09/17  
**Report Date** 16/09/17

## SURGICAL PATHOLOGY REPORT

### Benign cystic lesion , Cyst.

#### DIAGNOSIS

**BENIGN CYSTIC LESION**



#### SPECIMEN

Cyst.

#### GROSS

1) Received 1x3cm greyish white tissue piece .

#### Microscopy

- 1) Section examined shows Squamous lining epithelial having round to oval nucleus .
- 2) Deeper tissue shows fibrocollagenous tissue blood vessels and inflammatory cell (lymphocyte and plasma cell).
- 3) Section also shows cyst lining having columnar cells.
- 4) No granuloma seen.

**Note :** All biopsy specimen will be stored for 15 (fifteen)days, block and slides for 5(five) years only from the time of receipt at the laboratory. No request ,for any of the above ,will be entertained after the due date.

#### Reference

- i) Rosai and Ackerman's Surgical Pathology.
- ii) Modern Surgical Pathology.



**Gulshan Yadav, MD**  
**Consultant Pathologist**

Report generated at MolQ Laboratory, Gurgaon