

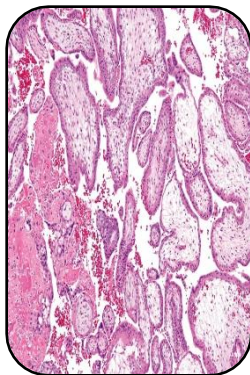
| | | | | | |
|---------------------|---------------|--------------------|-----------------------|--------------------------|----------|
| Patient Name | MRS ANITA | Client Name | Bio-Science X Ray Lab | Specimen Received | 12/09/17 |
| Age/Sex | 23/F | Client Code | MOLQ11139P | Specimen Type | Tissue |
| Patient ID | 011709120158 | Ref. Doctor | | Collection Date | 12/09/17 |
| Specimen ID | MOLQ/B-700/17 | | | Report Date | 16/09/17 |

SURGICAL PATHOLOGY REPORT

POC

DIAGNOSIS

ADVICE: KINDLY CORRELATE CLINICALLY AND RADIOLOGICALLY.



SPECIMEN

poc

GROSS

- 1) Received multiple greyish white tissue pieces.

Microscopy

- 1) Section examined shows tortuous endometrial glands having columnar lining epithelium.
- 2) Section also shows large number of RBC and inflammatory cells and blood vessels.
- 3) No trophoblastic cells seen.

Note : All biopsy specimen will be stored for 15 (fifteen)days, block and slides for 5(five) years only from the time of receipt at the laboratory. No request ,for any of the above ,will be entertained after the due date.

Reference

- i) Rosai and Ackerman's Surgical Pathology.
- ii) Modern Surgical Pathology.

Gulshan Yadav, MD
Consultant Pathologist

Report generated at MolQ Laboratory, Gurgaon