

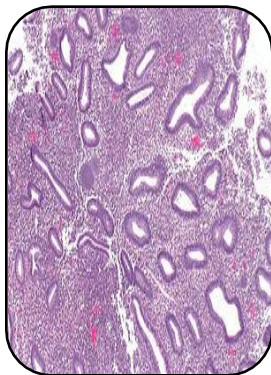
<b>Patient Name</b>	MRS. NEETU / PAWAN	<b>Client Name</b>	City Lab, Bhiwadi	<b>Specimen Received</b>	08/09/17
<b>Age/Sex</b>	26/F	<b>Client Code</b>	MOLQ1021CM	<b>Specimen Type</b>	Tissue
<b>Patient ID</b>	011709080189	<b>Ref. Doctor</b>		<b>Collection Date</b>	08/09/17
<b>Specimen ID</b>	MOLQ/B-692/17			<b>Report Date</b>	13/09/17

## SURGICAL PATHOLOGY REPORT

### Disordered proliferative phase , Endometrial Biopsy

#### DIAGNOSIS

**DISORDERED PROLIFERATIVE PHASE.**



#### SPECIMEN

Endometrial Biopsy

#### GROSS

- 1) Received multiple greyish white tissue piece .

#### Microscopy

- 1) Section examined shows small endometrial glands having round to oval nucleus with mononuclear Stroma.
- 2) No granuloma and no malignant cells seen.

**Note :** All biopsy specimen will be stored for 15 (fifteen)days, block and slides for 5(five) years only from the time of receipt at the laboratory. No request ,for any of the above ,will be entertained after the due date.

#### Reference

- i) Rosai and Ackerman's Surgical Pathology.
- ii) Modern Surgical Pathology.

A handwritten signature in black ink, appearing to read 'Gulshan', written over a white rectangular background.

**Gulshan Yadav, MD**  
**Consultant Pathologist**