

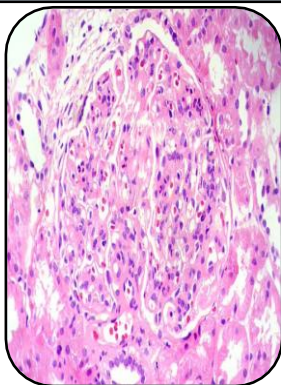
| | | | | | |
|---------------------|---------------|--------------------|------------------|--------------------------|----------|
| Patient Name | MRS. PUSHPA | Client Name | S.R. Diagnostics | Specimen Received | 30/08/17 |
| Age/Sex | 55/F | Client Code | MolQ1528CM | Specimen Type | Tissue |
| Patient ID | 011709030019 | Ref. Doctor | | Collection Date | 30/08/17 |
| Specimen ID | MOLQ/B-675/17 | | | Report Date | 10/09/17 |

SURGICAL PATHOLOGY REPORT

Cholecystitis with Cholelithiasis, Gall Bladder

DIAGNOSIS

CHOLECYSTITIS WITH CHOLELITHIASIS.



SPECIMEN:

Gall Bladder

GROSS :

- 1) Received 6x2.8cm long gall bladder. Cut section shows small stones.

Microscopy

- 1) Section examined shows ulcerative mucosa and Rokitansky-Aschoff sinuses with lymphocytes within fibrocollagenous tissue.

Note : All biopsy specimens will be stored for 15 (fifteen) days, block and slides for 5 (five) years only from the time of receipt at the laboratory. No request, for any of the above, will be entertained after the due date.

Reference

- i) Rosai and Ackerman's Surgical Pathology.
- ii) Modern Surgical Pathology.

Gulshan Yadav, MD
Consultant Pathologist