

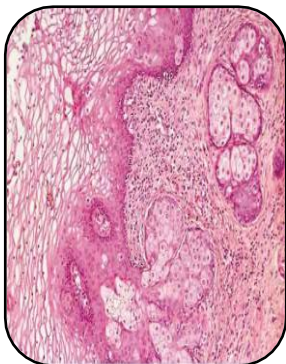
Patient Name	Mr. AMIT	Client Name	Gobind Hospital	Specimen Received	25/08/17
Age/Sex	23/M	Client Code	MOLQ1232P	Specimen Type	Tissue
Patient ID	011708250065	Ref. Doctor		Collection Date	25/08/17
Specimen ID	MOLQ/B-652/17			Report Date	29/08/17

SURGICAL PATHOLOGY REPORT

Infected sebaceous Cyst , sebaceous Cyst.

DIAGNOSIS

INFECTED SEBACEOUS CYST.



SPECIMEN

sebaceous Cyst.

GROSS

1) Received 1x1cm greyish white tissue piece.

Microscopy

- 1) Section examined shows Squamous lining epithelium with fibrocollagenous tissue with Perakerotosis.
- 2) No granuloma and no malignant cells seen with inflammatory cells.

Note : All biopsy specimen will be stored for 15 (fifteen)days, block and slides for 5(five) years only from the time of receipt at the laboratory. No request ,for any of the above ,will be entertained after the due date.

Reference

- i) Rosai and Ackerman's Surgical Pathology.
- ii) Modern Surgical Pathology.

Gulshan Yadav, MD
Consultant Pathologist