

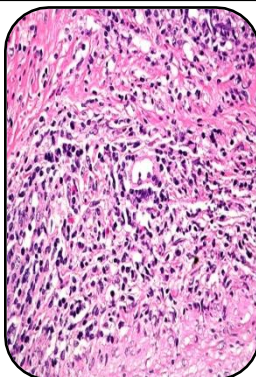
<b>Patient Name</b>	Mr. SHRI BHAGWAN	<b>Client Name</b>	Navjeevan Hospital (Rohtak)	<b>Specimen Received</b>	22/08/17
<b>Age/Sex</b>	42/M	<b>Client Code</b>	MOLQ 1297CM	<b>Specimen Type</b>	Tissue
<b>Patient ID</b>	011708220229	<b>Ref. Doctor</b>		<b>Collection Date</b>	22/08/17
<b>Specimen ID</b>	MOLQ/B-644/17			<b>Report Date</b>	29/08/17

## SURGICAL PATHOLOGY REPORT

### Chronic inflammatory cells , Granular Tissue

#### DIAGNOSIS

**CHRONIC INFLAMMATORY CELLS.**



#### SPECIMEN

Granular Tissue

#### GROSS

- 1) Received multiple greyish white tissue pieces.

#### Microscopy

- 1) Section examined shows fibrocollagenous tissue, mature adipose cells and mononuclear inflammatory cells (lymphocytes, plasma cells, histiocytes).
- 2) No malignant cells seen.

**Note :** All biopsy specimen will be stored for 15 (fifteen) days, block and slides for 5 (five) years only from the time of receipt at the laboratory. No request, for any of the above, will be entertained after the due date.

#### Reference

- i) Rosai and Ackerman's Surgical Pathology.
- ii) Modern Surgical Pathology.

A handwritten signature in black ink, appearing to read 'Gulshan'.

**Gulshan Yadav, MD**  
Consultant Pathologist