

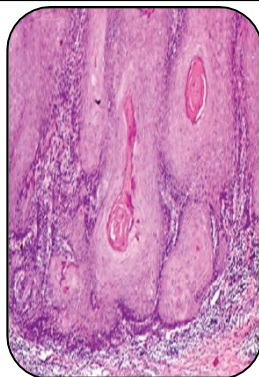
Patient Name	MR. HARPAL	Client Name	Shree Bala Ji Path Lab	Specimen Received	16/08/17
Age/Sex	69/M	Client Code	MOLQ1079P	Specimen Type	Tissue
Patient ID	011708160195			Collection Date	16/08/17
Specimen ID	MOLQ/B-629/17	Ref. Doctor		Report Date	22/08/17

SURGICAL PATHOLOGY REPORT

Hyperkerrototic Lesion , Excision Biopsy

DIAGNOSIS

HYPERKEROTOTIC LESION.



SPECIMEN

Excision Biopsy

GROSS

- 1) Received multiple greyish white tissue pieces.

Microscopy

- 1) Section examined shows Squamous lining epithelium having small round nucleus with hyperkeratosis with Parakeratosis with blood vessels.
- 2) No granuloma and no malignant cells seen.

Note : All biopsy specimen will be stored for 15 (fifteen)days, block and slides for 5(five) years only from the time of receipt at the laboratory. No request ,for any of the above ,will be entertained after the due date.

Reference

- i) Rosai and Ackerman's Surgical Pathology.
- ii) Modern Surgical Pathology.

Gulshan Yadav, MD
Consultant Pathologist