

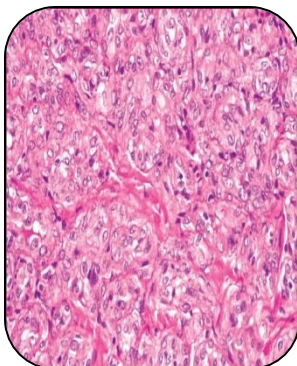
<b>Patient Name</b>	MRS. SHALLEY SHARMA	<b>Client Name</b>	Lifeaid Wellness Centre	<b>Specimen Received</b>	13/08/17
<b>Age/Sex</b>	28/F			<b>Specimen Type</b>	Tissue
<b>Patient ID</b>	011708130143	<b>Client Code</b>	MOLQ1476CM	<b>Collection Date</b>	13/08/17
<b>Specimen ID</b>	MOLQ/B-616/17	<b>Ref. Doctor</b>		<b>Report Date</b>	21/08/17

## SURGICAL PATHOLOGY REPORT

### proliferative phase , Endometrial Biopsy

#### DIAGNOSIS

**PROLIFERATIVE PHASE.**



#### SPECIMEN

Endometrial Biopsy

#### GROSS

1) Received multiple greyish white tissue pieces.

#### Microscopy

1) Section examined shows lining epithelium having cuboidal cells with oval nucleus.

**Note :** All biopsy specimen will be stored for 15 (fifteen)days, block and slides for 5(five) years only from the time of receipt at the laboratory. No request ,for any of the above ,will be entertained after the due date.

#### Reference

- i) Rosai and Ackerman's Surgical Pathology.
- ii) Modern Surgical Pathology.

**Gulshan Yadav, MD**  
**Consultant Pathologist**

*Report generated at MolQ Laboratory, Gurgaon*