

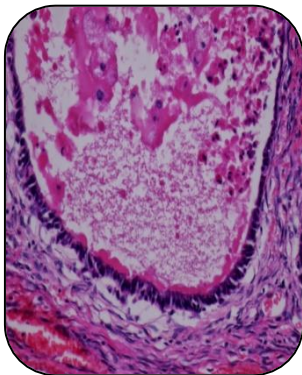
<b>Patient Name</b>	MRS PANMESHWARI	<b>Client Name</b>	Navjeevan Hospital (Rohtak)	<b>Specimen Received</b>	11/08/17
<b>Age/Sex</b>	70/F	<b>Client Code</b>	MOLQ 1297CM	<b>Specimen Type</b>	Tissue
<b>Patient ID</b>	011708110231	<b>Ref. Doctor</b>		<b>Collection Date</b>	11/08/17
<b>Specimen ID</b>	MOLQ/B-606/17			<b>Report Date</b>	17/08/17

## SURGICAL PATHOLOGY REPORT

### Benign Cystic Lesion , Oral cavity

#### DIAGNOSIS

**BENIGN CYSTIC LESION.**



#### SPECIMEN

Oral cavity

#### GROSS

1) Received 1x1cm cystic greyish white tissue piece.

#### Microscopy

- 1) Section examined shows lining epithelium having round oval nucleus with fibrocollagenous tissue, blood vessel.
- 2) No granuloma and no malignant cells seen.

**Note :** All biopsy specimen will be stored for 15 (fifteen)days, block and slides for 5(five) years only from the time of receipt at the laboratory. No request ,for any of the above ,will be entertained after the due date.

#### Reference

- i) Rosai and Ackerman's Surgical Pathology.
- ii) Modern Surgical Pathology.

**Gulshan Yadav, MD**  
Consultant Pathologist

Report generated at MolQ Laboratory, Gurgaon