

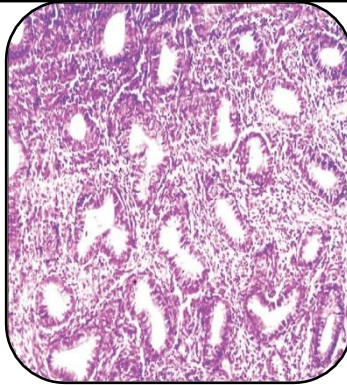
Patient Name	MRS. BHAGWATI	Client Name	Vedic Hospital	Specimen Received	04/08/17
Age/Sex	40/F	Client Code	MOLQ1492CM	Specimen Type	Tissue
Patient ID	011708040033	Ref. Doctor		Collection Date	04/08/17
Specimen ID	MOLQ/B-580/17			Report Date	08/08/17

SURGICAL PATHOLOGY REPORT

Simple Hyperplasia without Atypia , Endometrium Biopsy

DIAGNOSIS

SIMPLE HYPERPLASIA WITHOUT ATYPIA.



SPECIMEN

Endometrium Biopsy

GROSS

1) Received multiple greyish white tissue pieces.

Microscopy

- 1) Section examined shows few broken endometrial glands having small round nucleus.
- 2) Stroma shows mononuclear inflammatory cells and blood clot.
- 3) No malignant cells seen.
- 4) Few cystically dilated glands seen.

Note : All biopsy specimen will be stored for 15 (fifteen) days, block and slides for 5 (five) years only from the time of receipt at the laboratory. No request, for any of the above, will be entertained after the due date.

Reference

- i) Rosai and Ackerman's Surgical Pathology.
- ii) Modern Surgical Pathology.

Gulshan Yadav, MD
Consultant Pathologist