

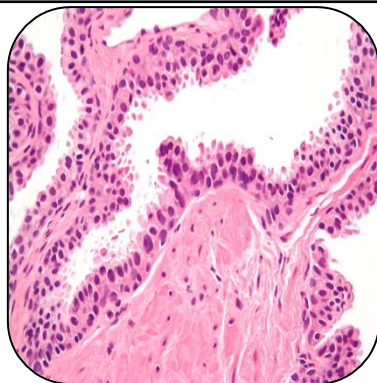
Patient Name	MR. RAJ KUMAR	Client Name	Navjeevan Hospital (Rohtak)	Specimen Received	12/07/17
Age/Sex	70/M	Client Code	MOLQ 1297CM	Specimen Type	Tissue
Patient ID	011707120188	Ref. Doctor		Collection Date	12/07/17
Specimen ID	MOLQ/B-519/17			Report Date	18/07/17

SURGICAL PATHOLOGY REPORT

Benign prostatic Hyperplasia, T.U.R.P

DIAGNOSIS

BENIGN PROSTATIC HYPERPLASIA.



SPECIMEN

T.U.R.P

GROSS

- 1) Received multiple greyish white tissue pieces.

Microscopy

- 1) Section examined shows bilayered prostatic glands with columnar lining epithelium and projection in the lumen with small round to oval nucleus surrounded by large number of fibrocollagenous tissue and mononuclear inflammatory cells.

Note : All biopsy specimen will be stored for 15 (fifteen)days, block and slides for 5(five) years only from the time of receipt at the laboratory. No request ,for any of the above ,will be entertained after the due date.

Reference

- i) Rosai and Ackerman's Surgical Pathology.
- ii) Modern Surgical Pathology.

Gulshan Yadav, MD
Consultant Pathologist

Report generated at MolQ Laboratory, Gurgaon