

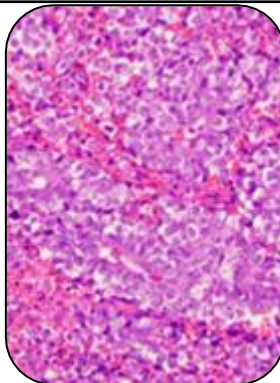
<b>Patient Name</b>	MRS. GUDDI DEVI	<b>Client Name</b>	Lifeaid Wellness Centre	<b>Specimen Received</b>	11/07/17
<b>Age/Sex</b>	43/F	<b>Client Code</b>	MOLQ1123CM	<b>Specimen Type</b>	Tissue
<b>Patient ID</b>	011707110007	<b>Ref. Doctor</b>		<b>Collection Date</b>	11/07/17
<b>Specimen ID</b>	MOLQ/B-512/17			<b>Report Date</b>	17/07/17

## SURGICAL PATHOLOGY REPORT

### Bartholin cyst.

#### DIAGNOSIS

**BARTHOLIN CYST.**



#### SPECIMEN

Bartholin Cyst

#### GROSS

1) Received 5.8x2.6cm greyish white tissue piece.

#### Microscopy

- 1) Section examined shows Squamous lining epithelium having small round fibrocollagenous tissue, small blood vessels, glands.
- 2) No granuloma and no malignant cells seen.

**Note :** All biopsy specimen will be stored for 15 (fifteen)days, block and slides for 5(five) years only from the time of receipt at the laboratory. No request ,for any of the above ,will be entertained after the due date.

#### Reference

- i) Rosai and Ackerman's Surgical Pathology.
- ii) Modern Surgical Pathology.

**Gulshan Yadav, MD**  
Consultant Pathologist