

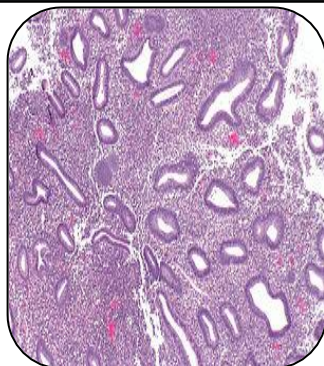
<b>Patient Name</b>	MR. NEERAJ	<b>Client Name</b>	Aditi Family Clinic	<b>Specimen Received</b>	07/07/17
<b>Age/Sex</b>	23/M	<b>Client Code</b>	MOLQ1538CM	<b>Specimen Type</b>	Tissue
<b>Patient ID</b>	011707080122	<b>Ref. Doctor</b>	DR. REENA KAWATRA	<b>Collection Date</b>	07/07/17
<b>Specimen ID</b>	MOLQ/B-502/17			<b>Report Date</b>	14/07/17

## SURGICAL PATHOLOGY REPORT

### PROLIFERATIVE PHASE , Endometrial Biopsy

#### DIAGNOSIS

**PROLIFERATIVE PHASE.**



#### SPECIMEN:

Endometrial Biopsy

#### GROSS:

1) Received multiple greyish white tissue piece.

#### Microscopy

- 1) Section examined shows small endometrial glands having cuboidal lining epithelium with small round oval nucleus.
- 2) Stroma shows mononuclear inflammatory cells.
- 3) No granuloma and no malignant cells seen.

**Note :** All biopsy specimen will be stored for 15 (fifteen)days, block and slides for 5(five) years only from the time of receipt at the laboratory. No request ,for any of the above ,will be entertained after the due date.

#### Reference

- i) Rosai and Ackerman's Surgical Pathology.
- ii) Modern Surgical Pathology.

**Gulshan Yadav, MD**  
Consultant Pathologist