

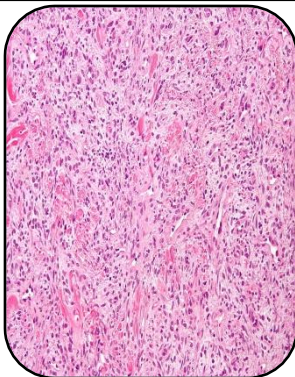
Patient Name MRS. MEENA DEVI	Client Name Star Hospital	Specimen Received 07/07/17
Age/Sex 35/F		Specimen Type Tissue
Patient ID 011707070169	Client Code MOLQ1255CM	Collection Date 07/07/17
Specimen ID MOLQ/B-502/17	Ref. Doctor DR. DEEP SHIKHA	Report Date 13/07/17

SURGICAL PATHOLOGY REPORT

Proliferative phase, Endometrium

DIAGNOSIS

PROLIFERATIVE PHASE.



SPECIMEN

Endometrium

GROSS

- 1) Received multiple greyish white tissue pieces.

Microscopy

- 1) Section examined shows small endometrial glands having cuboidal lining epithelium with small round oval nucleus.
- 2) Stroma shows mononuclear inflammatory cells.
- 3) No granuloma and no malignant cells seen.

Note : All biopsy specimen will be stored for 15 (fifteen) days, block and slides for 5 (five) years only from the time of receipt at the laboratory. No request, for any of the above, will be entertained after the due date.

Reference

- i) Rosai and Ackerman's Surgical Pathology.
- ii) Modern Surgical Pathology.

A handwritten signature in black ink, appearing to read 'Gulshan', written over a white rectangular background.

Gulshan Yadav, MD
Consultant Pathologist

Report generated at MolQ Laboratory, Gurgaon